

Isavuconazole or Voriconazole for Fungal Infection Prophylaxis in Lung Transplant Recipients- A Retrospective Cohort Analysis

Claire (Lujia) Yang, Dennis Bourkov
Kevin Forrester, PharmD

INTRODUCTION

Lung transplant recipients are maintained in immunosuppressed states with the goal of preventing transplant rejection. Associated toxicities include fungal infections with the most concerning of these being *Aspergillus*, as *Aspergillus* infection has been found to be an independent risk factor for chronic lung transplant rejection. In prior years, a commonly used fungal prophylaxis agent in this population has been voriconazole (Vfend), a triazole antifungal. However, a common adverse effect associated with voriconazole is photosensitivity, which when coupled with the increased propensity for malignancy resultant from transplant immunosuppressive therapies, has been associated with increased incidences of squamous cell carcinoma. Voriconazole is also notable for inhibition of CYP450 isoenzymes and hepatotoxicity. Isavuconazole (Cresemba), a more recently developed triazole antifungal, has not been reported to be associated with photosensitivity. Currently, both agents are FDA approved for the treatment of invasive fungal infection but are not FDA approved for use in fungal infection prophylaxis.

OBJECTIVE

There is a scarcity of data on the relative merits of isavuconazole as compared with voriconazole for fungal infection prophylaxis in lung transplant recipients. This study assesses the relative efficacy and safety of isavuconazole for fungal, particularly *Aspergillus*, prophylaxis in lung transplant recipients.

MATERIALS AND METHODS

This is a retrospective cohort study that includes all patients who received a lung transplant at the Keck Hospital of University of Southern California (USC) between January 2013 and July 2019, which yielded a total of 99 patients. After review of electronic medical records, 3 patients were excluded: 1 expired within 6 months, 1 received two lung transplants on separate dates, and 1 received posaconazole prophylaxis. After accounting for these exclusions, 96 patients were stratified according to the antifungal prophylaxis they were given for 6 months: voriconazole (34 patients), isavuconazole (36 patients), or no prophylaxis (26 patients). The primary end points were incidence of fungal infection at 6 months, incidence of first *Aspergillus* infection, and time to first *Aspergillus* infection. A patient was considered to have developed fungal infection if records indicated growth positive fungal cultures. Organism identification was likewise derived from fungal culture data. The secondary end points were incidence of hepatotoxicity at 6 months and time to hepatotoxicity. Hepatotoxicity was defined as either an ALT or AST greater than or equal to 3 times the patient's baseline ALT or AST at date of transplant. If ALT/AST was not available at date of transplant, the next consecutive date of data availability was selected as baseline. The assessed prophylaxis regimens were voriconazole 6 mg/kg IV every 12 hours for 2 doses, followed by voriconazole 200 mg PO twice daily for 6 months or isavuconazole 372 mg (PO or IV) every 8 hours for 6 doses, followed by isavuconazole 186 mg PO twice daily for 6 months.

RESULTS

Table 1. Characteristics of Patients at Baseline

Characteristic	Isavuconazole Group (N=34)	Voriconazole Group (N=36)	No Prophylaxis Group (N=26)
Age – yr (SD)	56 (8)	48 (16)	54 (12)
Male sex – no. (%)	19 (55.9%)	13 (36.1%)	15 (57.7%)
Diagnosis at admission – no. (%)			
COPD	11 (32.4%)	6 (16.7%)	8 (30.8%)
Interstitial Lung Disease	12 (35.3%)	7 (19.4%)	3 (11.5%)
Intrapulmonary Fibrosis (including Scleroderma)	7 (20.6%)	8 (22.2%)	13 (50.0%)
Cystic Fibrosis	1 (2.9%)	13 (36.1%)	0 (0%)
Other ∇	3 (8.8%)	2 (5.6%)	2 (7.7%)
Transplant Type – no. (%)			
Single Lung	31 (85.3%)	15 (41.7%)	18 (69.2%)
Double Lung	5 (14.7%)	21 (58.3%)	8 (30.8%)

∇ Other diagnoses include bronchiectasis, sarcoidosis, emphysema, and nonspecific interstitial pneumonia.

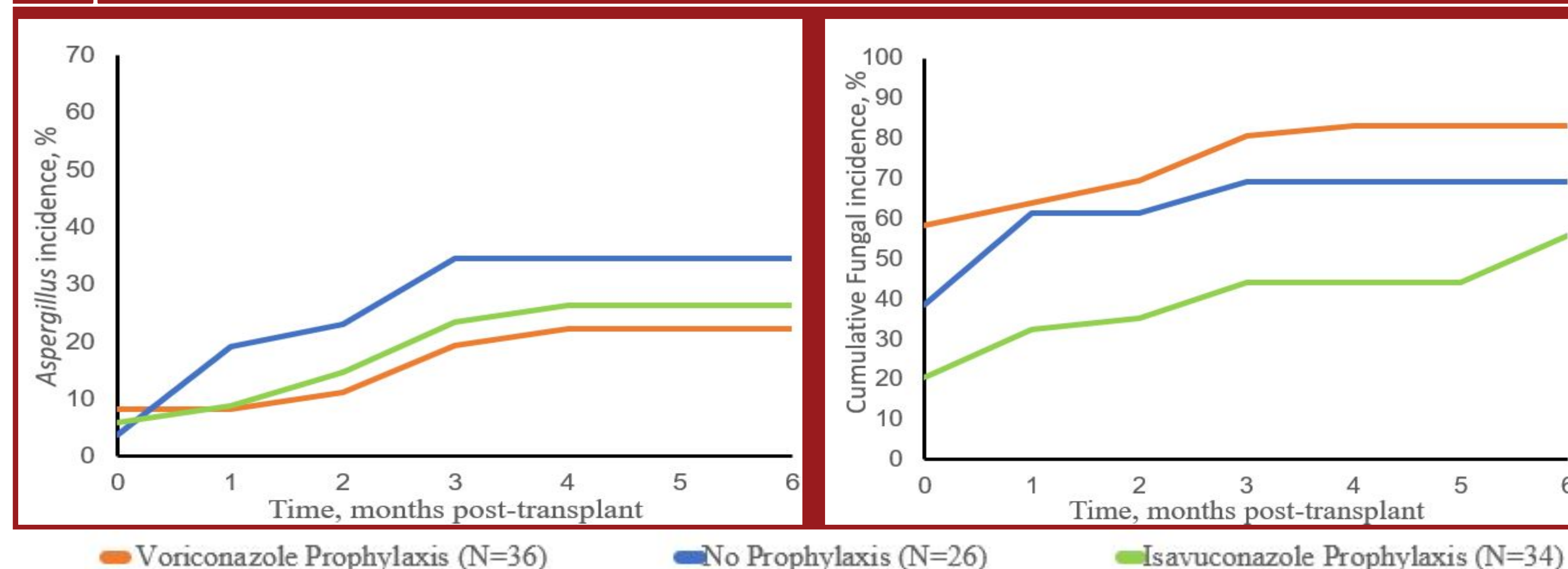
Table 2. Clinical End Points

End Point	Isavuconazole Group (N=34)	Voriconazole Group (N=36)	No Prophylaxis Group (N=26)	Hazard Ratio ^o
Primary end point: Incidence of fungal infection at 6 months – no. (%)	19 (55.9%)	30 (83.3%)	18 (69.2%)	Isavuconazole: 0.81 Voriconazole: 1.20
<i>Aspergillus</i> Infection – no (%)	9 (26.5%)	8 (22.2%)	9 (34.6%)	Isavuconazole: 0.76 Voriconazole: 0.64
Time to <i>Aspergillus</i> Infection – days (SD)	74.1 (44.9)	70.5 (52.2)	64.9 (30.1)	
Secondary end point: Incidence of hepatotoxicity at 6 months –no. (%) ^{3o}	18 (52.9%)	29 (80.5%)	16 (61.5%)	Isavuconazole: 0.86 Voriconazole: 1.31
Time to hepatotoxicity – days (SD)	42 (43)	18 (29)	16 (24)	

^{3o} Hepatotoxicity is defined as AST or ALT greater than or equal to 3 times the patient's baseline values.

^o The hazard ratios for isavuconazole and voriconazole were calculated using the percentages of endpoint for isavuconazole/no prophylaxis and percentage of endpoint for voriconazole/no prophylaxis, respectively.

Figures 1 and 2. Incidence of *Aspergillus* (Left) and Cumulative Fungal Infection (Right) at 6 Months After Lung Transplant



DISCUSSION

The difference in incidence of *Aspergillus* infection throughout the 6 month post-transplant prophylaxis period between isavuconazole prophylaxis and voriconazole prophylaxis was found to not be statistically significant (p=0.32). Statistically significant differences in the 6 month incidence of *Aspergillus* infection were observed for both voriconazole (p=0.0002) and isavuconazole (p=0.004) relative to patients receiving no prophylaxis. There was a statistically significant difference in cumulative fungal infection between isavuconazole prophylaxis and no prophylaxis (p<0.0001). Patients receiving voriconazole prophylaxis were found to have a greater incidence of cumulative fungal infection throughout the 6 month post-transplant prophylaxis period. This finding may be confounded by the fact that voriconazole prophylaxis is chosen for all patients with a history of *Aspergillus* infection prior to lung transplant and that a greater proportion of patients on the voriconazole regimen received double lung transplants; these may potentially serve as independent risk factors for the development of future fungal infections. A strength of the study was that it assessed all appropriate lung transplant recipients within a significant (5 year) timeframe. A limitation of this study was that it did not assess the efficacy of isavuconazole in patients with history of *Aspergillus* prior to lung transplant. Additionally, this study did not have the necessary follow-up time to assess for development of phototoxicity and carcinoma, as these effects may take numerous years to manifest. Another limitation was the inability to differentiate between antifungal mediated hepatotoxicity and that which is caused by other components of a transplant recipients' immunosuppression regimens.

CONCLUSION

This study demonstrated that isavuconazole is noninferior to voriconazole for prophylaxis against *Aspergillus* infections and cumulative fungal infections in lung transplant recipients.

ACKNOWLEDGEMENTS

The authors would like to acknowledge the expertise, guidance, and support of Dr. Kevin Forrester and Dr. Sivagini Ganesh at Keck Hospital of USC.

REFERENCES

- Husain S, Camargo JF. Invasive Aspergillosis in solid-organ transplant recipients: Guidelines from the American Society of Transplantation Infectious Diseases Community of Practice. *Clin Transplant*. 2019;e13544.
- Maertens JA, Raad II, Marr KA, et al. Isavuconazole versus voriconazole for primary treatment of invasive mould disease caused by *Aspergillus* and other filamentous fungi (SECURE): a phase 3, randomized-controlled, non-inferiority trial. *Lancet*. 2016;387(10020):760-769.
- Pettit NN, Carver PL. Isavuconazole: A New Option for the Management of Invasive Fungal Infections. *Ann Pharmacother*. 2015;49(7):825-842.
- Gräger N, Leffler M, Gottlieb J, et al. Risk Factors for Developing Nonmelanoma Skin Cancer after Lung Transplantation. *J Skin Cancer*. 2019;7089482.
- Tang H, Shi W, Song Y, Han J. Voriconazole exposure and risk of cutaneous squamous cell carcinoma among lung or hematopoietic cell transplant patients: A systemic review and meta-analysis. *J Am Acad Dermatol*. 2019;80(2):500-507.
- Pennington KM, Razonable RR, Peters S, et al. Why do lung transplant patients discontinue triazole prophylaxis? *Transpl Infect Dis*. 2019;e13067.
- Marchesi F, Girmenia C, Goffredo BM. Isavuconazole: Case Report and Pharmacokinetic Considerations. *Chemotherapy*. 2018;63(5):253-256.
- Husain S, Paterson DL, Studer S, et al. Voriconazole Prophylaxis in Lung Transplant Recipients. *Am J Transplant*. 2006;6(12):3008-3016.
- Weigt SS, Finlen-Copeland CA, Derhovanessian A, et al. Colonization With Small Conidia *Aspergillus* Species Is Associated With Bronchiolitis Obliterans Syndrome: A Two-Center Validation Study. *Am J Transplant*. 2013;13(4):919-927.